
A Prospective, Randomized, Controlled Trial of 2-Octylcyanoacrylate Versus Suture Repair for Nail Bed Injuries

Eric J. Strauss, MD, Wayne M. Weil, MD, Charles Jordan, MD, Nader Paksima, DO

Purpose To prospectively compare the efficacy of 2-octylcyanoacrylate (Dermabond; Ethicon Inc, Somerville, NJ) with standard suture repair in the management of nail bed lacerations.

Methods Forty consecutive patients with acute nail bed lacerations were enrolled in this study. Eighteen patients were randomized to nail bed repair using Dermabond (2-octylcyanoacrylate), and 22 were randomized to standard repair using 6-0 chromic suture. At presentation, demographic information and laceration characteristics were recorded. The time required for nail bed laceration repair with each method was documented, and cosmetic and functional outcomes were assessed at 1, 3, and 6 months after injury. Comparisons between treatment groups were made using unpaired Student's *t*-tests.

Results The Dermabond repair group was composed of 10 males and 8 females with a mean age of 32.3 years. The suture repair group was composed of 17 males and 5 females with a mean age of 29.5 years. The mean follow-up was 5.1 months (range 4–11 months) and 4.8 months (range 4–11 months) for the Dermabond group and suture group, respectively. There was no difference between the two treatment groups with respect to age, comorbidities, and length of follow-up ($p > .05$). The average time required for nail bed repair using Dermabond was 9.5 minutes, which was significantly less than that required for suture repair (27.8 minutes) ($p < .0003$). At each follow-up time point, there was no statistical difference in physician-judged cosmesis, patient-perceived cosmetic outcome, pain, or functional ability between the Dermabond and suture treatment cohorts ($p > .05$).

Conclusions Nail bed repair performed using Dermabond is significantly faster than suture repair, and it provides similar cosmetic and functional results. In the management of acute nail bed lacerations, Dermabond is an efficient and effective repair technique. (*J Hand Surg* 2008;33A:250–253. Copyright © 2008 by the American Society for Surgery of the Hand.)

Type of study/level of evidence Therapeutic I.

Key words Dermabond, nail bed laceration, repair.

FINGERTIP INJURIES, ESPECIALLY THOSE affecting the nail bed, are among the most common traumatic conditions presenting to hand surgeons and emergency departments. Removal of the nail plate and

inspection of the injury coupled with nail bed repair with fine, absorbable suture has been the treatment of choice for these injuries.^{1–3} Meticulous repair of nail bed lacerations along with replacement of the nail between the eponychial fold and underlying matrix has been shown to prevent long-term cosmetic and functional disability.²

The cyanoacrylate group of tissue adhesives has been used extensively in both traumatic and surgical wound closures. This material polymerizes upon contact with a fluid or basic substance creating a strong, stable bond.⁴ A number of studies in the emergency medicine, plastic and hand surgery literature have demonstrated that cyanoacrylate tissue adhesives are as effective as suture in the management of lacerations, producing a fast and cosmetic closure.^{4–8}

To date there have been no controlled trials comparing the use of 2-octylcyanoacrylate, more commonly known as Dermabond (Ethicon, Inc., Somerville, NJ), versus suture to repair nail bed lacerations. Recent studies by both Stanislas et al and Richards et al reported good results using a tissue adhesive to secure the nail plate under the eponychial fold after suture repair of nail bed injuries.^{9,10}

From the Department of Orthopaedic Surgery, NYU–Hospital for Joint Diseases, New York, NY; Division of Hand and Microvascular Surgery, Department of Orthopaedic Surgery, University of Washington Medical Center, Seattle, WA.

Received for publication May 30, 2007; accepted in revised form October 10, 2007.

No benefits in any form have been received or will be received from a commercial party related directly or indirectly to the subject of this article.

Corresponding author: Nader Paksima, DO, Department of Orthopaedic Surgery, NYU–Hospital For Joint Diseases, 530 First Avenue, Suite 8U, New York, NY 10016; e-mail: npaksima@yahoo.com.

0363-5023/08/33A02-0017\$34.00/0
doi:10.1016/j.jhssa.2007.10.008

The current study was undertaken to prospectively compare the efficacy of 2-octylcyanoacrylate (Dermabond, Ethicon Inc, Somerville, NJ) with standard suture repair in the management of nail bed lacerations. We hypothesized that nail bed laceration repair with Dermabond would be significantly faster than standard suture repair, while providing similar cosmetic and functional results.

MATERIALS AND METHODS

Forty consecutive patients with acute nail bed lacerations presenting within 8 hours of injury were enrolled in this Institutional Review Board–approved, prospective, randomized, controlled trial. Inclusion criteria included patients with a nail plate avulsion injury with associated nail bed laceration and those with greater than 50% subungual hematoma with an intact nail plate. Patients with nail bed injuries from bite wounds were excluded from the study.

Upon initial evaluation, the purpose of the study was explained to the patients, and informed consent for participation was obtained. Patients were then randomly assigned to either Dermabond repair or suture repair based on the last digit of their assigned hospital medical record number. Even-numbered patients were randomized to the Dermabond treatment arm, and odd-numbered patients were randomized to the suture repair arm.

At presentation, each patient's demographic information, including age, past medical history, hand dominance, and mechanism of injury was recorded. All patients, regardless of the treatment arm to which they were randomized, underwent a thorough clinical examination under digital nerve block, with removal of the nail plate, wound irrigation, and debridement of devitalized tissue as previously described.^{1,3,11} Each patient received tetanus prophylaxis and a single dose of intravenous cefazolin in the emergency department. Laceration characteristics, as well as the time required to perform the nail bed repair using each treatment method, were documented. The treatment time was defined as the total elapsed time from the moment the tourniquet was applied to the time the nail plate was secured under the eponychial fold. Nail bed repair included the use of either Dermabond or 6-0 chromic suture material. After the nail bed repair, the nail plate was secured under the eponychial fold with either Dermabond or suture, depending on the assigned treatment arm.^{9,10} A nonadherent sterile dressing was then applied to the affected digit, and each patient was discharged with a 5-day course of cephalexin for prophylaxis against infection.

Follow-up evaluation included a wound check at 1 week after repair and examinations at 1 month, 3 months and 6 months. At each follow-up visit, patient-perceived functional outcome, cosmetic outcome, and level of pain were assessed using 3 separate 10-point analog scales. On the 10-point functional outcome scale, scores ranged from zero, which indicated complete loss of affected digit function during activities of daily living and recreational activities, to a score of 10, which indicated no functional limitation, with the patient using the affected digit without difficulty. With

the 10-point cosmetic outcome scale, patients expressed their satisfaction with the appearance of their treated finger, with scores ranging from zero, indicating a cosmetically unacceptable finger secondary to the presence of significant nail deformity, persistent swelling, or discoloration, to 10, which indicated no perceived difference between the treated finger and the same finger on the contralateral hand. Level of post-treatment pain was similarly assessed, with pain scores ranging from zero, indicating no pain related to the affected finger, to 10, which indicated persistent finger pain during both activity and rest.

Cosmetic results were also evaluated by the examining physician using a previously validated physician-based outcome tool developed by Zook et al.³ Based on this scoring system, an excellent outcome for the repaired finger was defined as those that were identical in appearance to the same finger on the contralateral hand. A very good result exhibited 1 variation from identical, such as incomplete adherence, nail ridging, split nails, or eponychial deformity. A good result exhibited 2 minor variations from identical. A poor cosmetic result exhibited more than 3 variations or 1 major variation from the same finger on the contralateral hand. Fingernails grow at an average rate of 1 mm per week; therefore, we chose a minimum of 4 months of follow-up for this study because it provided adequate time for a new nail to grow in.

Eighteen patients were randomized to the Dermabond treatment group. There were 10 males and 8 females with a mean age of 32.3 years (range 8–92 years). The suture repair group was composed of 17 males and 5 females with a mean age of 29.5 years (range 2–88 years). There was no significant difference between the two patient cohorts with respect to patient age, medical comorbidities, and length of post-injury follow-up ($p > .05$) (Table 1).

Comparisons were made between the 2 treatment cohorts with respect to the time required for repair of the nail bed laceration, patient-assessed cosmetic and functional outcomes, and physician-assessed cosmetic appearance after repair. Statistical evaluation of the data was performed using chi-square testing for the categorical data and unpaired Student's *t*-tests for the continuous data. Significance was defined as a *p* value of < 0.05 .

RESULTS

Within the Dermabond cohort, there were 12 patients with simple lacerations, 3 with stellate lacerations, 2 with crush-type lacerations, and 1 with an avulsion-type laceration. The suture group had 13 patients with simple lacerations, 6 with stellate lacerations, and 3 with crush-type lacerations. There was no statistical difference between the two groups with respect to laceration type sustained ($p > .05$), with a vast majority of the patients in the study sustaining simple and stellate lacerations. The dominant hand was injured in 8 of 18 (44%) cases in the Dermabond cohort and 10 of 22 (45%) in the suture repair cohort. Associated fractures were present in 8 of 18 cases (44%) and 9 of 22 cases (41%) in the Dermabond group and suture repair group, respectively

TABLE 1: Demographics and Injury Characteristics

| | Dermabond Repair | Suture Repair |
|------------------------|---|---|
| Number of patients | 18 | 22 |
| Mean age (range) | 32.3 y (4–92) | 29.9 y (2–88) |
| Laceration type | 12 simple lacerations 3 stellate lacerations 2 crush injuries 1 nail avulsion laceration | 13 simple lacerations 6 stellate lacerations 3 crush injuries |
| Dominant hand affected | 8/18 (44%) | 10/22 (45%) |
| Associated fracture | 8/18 (44%) | 9/22 (41%) |

(Table 1). The average time required for nail bed repair for the Dermabond treatment group was 9.5 minutes, which was significantly less than that required for suture repair (27.8 minutes) ($p < .0003$) (Figure 1).

The length of the follow-up period averaged 5.1 months (range 4–11 months) for the Dermabond group and 4.8 months (range 4–11 months) for the suture group. Physician-evaluated cosmetic appearance assessed at the most recent follow-up resulted in 15 excellent, 2 very good, and 1 poor result in the Dermabond group. Within the suture repair group, there were 17 fingers with an excellent result, 4 with a very good result, and 1 with a good result. The 1 poor result in the Dermabond group was a 32-year-old male smoker who required a revision using suture repair at 2 weeks because of the development of infection. Comparison of the physician-assessed cosmetic outcome between the two treatment groups demonstrated no significant difference ($p > .05$).

At the most recent (6-month) follow up, on the 10-point scale of patient-perceived cosmetic appearance, the mean score was 9.8 for the Dermabond treatment group and 10 for the suture repair group. Pain scores averaged 1.1 for the Dermabond group and 1.0 for the suture group. Functional scores related to the use of the repaired digit in activities of daily living averaged 9.9 for the Dermabond group and 10 for the suture group. There was no significant difference in patient-perceived cosmetic outcome, pain, or ability to use the repaired digit in activities of daily living between the Dermabond and suture treatment patient cohorts ($p > .05$) (Figure 1).

DISCUSSION

Nails improve hand function by enabling us to grasp small objects, increase tactile sensation, and function as an integral

part of the regulatory mechanism for circulation to the fingertip.¹² If meticulous repair of nail bed laceration edges is not obtained, nail deformity is likely to occur, which can lead to long-term cosmetic and functional disability.¹ The importance of meticulous anatomic repair of nail bed lacerations has been previously established.^{1,3,13} Immediate repair of nail bed lacerations generally results in a good functional and cosmetic outcome. The results of revision nail bed repairs with local and free tissue transfers are generally poorer than those of acute repair. In our prospective comparison of Dermabond with suture repair for the management of acute nail bed lacerations, we found that nail bed repair performed using Dermabond was significantly faster than suture repair, while providing similar cosmetic and functional results. Although 1 patient in the Dermabond group required revision at 2 weeks, the final functional and cosmetic result was excellent.

Our study population was similar to that of previously published series in terms of patient age, mechanism of injury, and laceration type. The cosmetic outcomes were also comparable to those previously reported in the literature. In a series of 184 nail bed injuries treated with suture repair over a 5.5-year period, Zook et al reported that at a minimum of 6 months of follow up, 90% of patients had good to excellent cosmetic outcomes.³ These results are comparable to the 94% good to excellent outcomes seen among patients in our study treated with Dermabond repair (17 of 18 cases) and the 100% good to excellent results seen in the suture treatment cohort (22 of 22 cases). In Zook's study, poor results occurred in association with crush injuries, avulsion injuries, and those complicated by the development of infection. Similarly, in our study, the 1 poor outcome occurred after the Dermabond repair became infected, requiring repair revision using a suture technique.

Some of the possible limitations to this study are that the

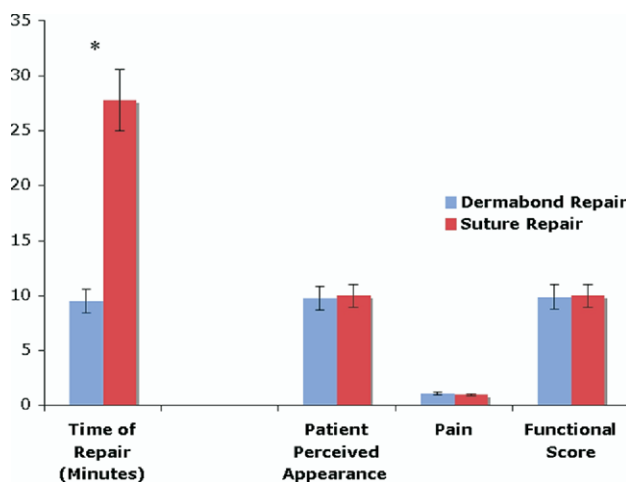


FIGURE 1: Repair of acute nail bed lacerations using Dermabond versus suture repair (* denotes statistically significant difference between treatment groups).

repairs were not performed under loupe magnification as previously described. The repairs were also performed by a heterogeneous group of orthopedic surgery residents under supervision of a heterogeneous group of attending physicians. Some residents performed only Dermabond repairs, while others performed only suture repair. However, the heterogeneity of the surgeons means that these results can be generalized. Our sample sizes were relatively small, but they were large enough to show a statistical difference in time of repair.^{14,15}

REFERENCES

1. Ashbell TS, Kleinert HE, Putcha SM, Kutz JE. The deformed finger nail, a frequent result of failure to repair nail bed injuries. *J Trauma* 1967;7:177–190.
2. Stevenson TR. Fingertip and nailbed injuries. *Orthop Clin North Am* 1992;23:149–159.
3. Zook EG, Guy RJ, Russell RC. A study of nail bed injuries: causes, treatment, and prognosis. *J Hand Surg* 1984;9A:247–252.
4. Sinha S, Naik M, Wright V, Timmons J, Campbell AC. A single blind, prospective, randomized trial comparing n-butyl 2-cyanoacrylate tissue adhesive (Indermil) and sutures for skin closure in hand surgery. *J Hand Surg* 2001;26B:264–265.
5. Quinn J, Wells G, Sutcliffe T, Jarmuske M, Maw J, Stiell I, Johns P. A randomized trial comparing octylcyanoacrylate tissue adhesive and sutures in the management of lacerations. *JAMA* 1997;277:1527–1530.
6. Quinn JV, Drzewiecki A, Li MM, Stiell IG, Sutcliffe T, Elmslie TJ, Wood WE. A randomized, controlled trial comparing a tissue adhesive with suturing in the repair of pediatric facial lacerations. *Ann Emerg Med* 1993;22:1130–1135.
7. Singer AJ, Hollander JE, Valentine SM, Turque TW, McCuskey CF, Quinn JV. Prospective, randomized, controlled trial of tissue adhesive (2-octylcyanoacrylate) vs standard wound closure techniques for laceration repair. *Stony Brook Octylcyanoacrylate Study Group. Acad Emerg Med* 1998;5:94–99.
8. Singer AJ, Quinn JV, Clark RE, Hollander JE. Closure of lacerations and incisions with octylcyanoacrylate: a multicenter randomized controlled trial. *Surgery* 2002;131:270–276.
9. Stanislas JM, Waldram MA. Keep the nail plate on with Histoacryl. *Injury* 1997;28:507–508.
10. Richards AM, Crick A, Cole RP. A novel method of securing the nail following nail bed repair. *Plast Reconstr Surg* 1999;103:1983–1985.
11. Zook EG. Reconstruction of a functional and aesthetic nail. *Hand Clin* 2002;18:577–594, v.
12. Zook EG. Anatomy and physiology of the perionychium. *Clin Anat* 2003;16:1–8.
13. Fassler PR. Fingertip injuries: evaluation and treatment. *J Am Acad Orthop Surg* 1996;4:84–92.
14. Guy RJ. The etiologies and mechanisms of nail bed injuries. *Hand Clin* 1990;6:9–19; discussion 21.
15. Brown RE. Acute nail bed injuries. *Hand Clin* 2002;18:561–575.